Rhinosinusitis:
Update on Diagnosis and Management

KAREN H. CALHOUN, MD, FACS
MINKA L. SCHOFIELD, MD

Ohio State University

ABSTRACT: The diagnosis of acute rhinosinusitis is based on the history and physical findings of nasal congestion, purulent rhinorrhea or post-nasal drainage, and facial pain or pressure. Most cases of acute rhinosinusitis are viral and do not benefit from antibiotics. For acute bacterial rhinosinusitis, the first line of therapy is amoxicillin; trimethoprim-sulfamethoxazole and the macrolides are reasonable alternatives for patients with penicillin allergy. Chronic rhinosinusitis is primarily a clinical diagnosis, but confirmation by CT or nasal endoscopy is advisable. The sinus CT scan is usually obtained when the patient is least symptomatic. Consider sinonasal surgery for patients with refractory chronic rhinosinusitis and for those with anatomic abnormalities that contribute to recurrent acute bacterial rhinosinusitis. Surgery can provide effective symptom relief and infection resolution. Factors that may predispose to or exacerbate rhinosinusitis include allergy and immune dysfunction, acid reflux, and disorders of mucociliary clearance.

Key words: rhinosinusitis, sinusitis, allergy

Twenty million cases of rhinosinusitis are diagnosed each year, and medical costs to manage this condition in the United States alone are in the billions of dollars.[1] Rhinosinusitis (sinus inflammation rarely exists without concomitant nasal inflammation) can be subdivided based on the timing of symptoms[2]:

- Acute rhinosinusitis typically denotes symptoms present for 4 weeks or less.
- Recurrent acute rhinosinusitis is 4 or more episodes of acute rhinosinusitis per year with resolution of symptoms between episodes.
- Subacute rhinosinusitis pertains to symptoms that have been present for more than 4 weeks but less than 3 months.
- Chronic rhinosinusitis is defined by the presence of symptoms for at least 3 months and can occur with or without periods of acute exacerbation and with or without nasal polyposis.

In this article, we discuss the diagnosis and management of acute and chronic rhinosinusitis. We also describe underlying conditions that can predispose to or exacerbate rhinosinusitis.

Dr Calhoun is professor in the department of otolaryngology–head and neck surgery at Ohio State University College of Medicine in Columbus, Ohio. Dr Schofield is assistant professor in the department of otolaryngology–head and neck surgery at Ohio State University College of Medicine.

ACUTE RHINOSINUSITIS

Diagnosis. The 1997 Task Force on Rhinosinusitis of the American Academy of Otolaryngology–Head and Neck Surgery recommended diagnosing acute rhinosinusitis based on major and minor criteria.[3] The primary major criteria are nasal obstruction or blockage, rhinorrhea or post-nasal discharge, and a change in the sense of smell. The secondary major criteria (ie, they need to accompany a major criterion to "count") are facial pain, pressure or fullness, and fever (acute rhinosinusitis only). The minor criteria are headache, fever (non-acute rhinosinusitis), halitosis, fatigue, dental pain, cough, and ear pressure or fullness. These guidelines suggest that acute sinusitis is present if the patient has two or more of the major criteria or one major criterion with two or more minor criteria, or frank pus seen on examination. Although this diagnostic paradigm is helpful, its complexity limits its usefulness.

The 2007 Task Force updated and simplified these recommendations.[4] They suggest that the diagnosis of acute rhinosinusitis should be based on the presence of nasal congestion, purulent (not clear) rhinorrhea or post-nasal drainage, and facial pain/pressure (**Table 1**).

Acute rhinosinusitis remains a clinical diagnosis that is based on patient history and physical examination. Transillumination and facial palpation for sinus tenderness do not improve diagnostic accuracy. Only in rare situations (see below) is imaging appropriate when considering the diagnosis of acute rhinosinusitis.

Distinguishing between viral rhinosinusitis and acute bacterial rhinosinusitis is challenging and vitally important. Of the 20 million cases of acute sinusitis that occur in the United States each year, a modest proportion are bacterial sinusitis (fewer than 10%, probably fewer than 2%). Prescribing antibiotics for the 90 to 98 patients of every 100 with acute rhinosinusitis of viral origin would be expensive and wasteful. But how best to identify the patients who will benefit from antibiotics?

Table 1 – Classification of acute rhinosinusitis

Acute rhinosinusitis

Up to 4 weeks of *purulent nasal drainage* (anterior, posterior, or both) accompanied by *nasal obstruction, facial pain-pressure-fullness,* or both:

- *Purulent nasal discharge* is cloudy or colored, in contrast to the clear secretions that typically accompany viral upper respiratory tract infection, and may be reported by the patient or observed on physical examination.
- *Nasal obstruction* may be reported by the patient as nasal obstruction, congestion, blockage, or stuffiness, or may be diagnosed by physical examination.
- *Facial pain-pressure-fullness* may involve the anterior face or periorbital region, or manifest with headache that is localized or diffuse.

Viral rhinosinusitis (VRS)

Acute rhinosinusitis that is caused by, or is presumed to be caused by, viral infection. Diagnose VRS when symptoms or signs of acute rhinosinusitis are present less than 10 days and the symptoms are not worsening.

Acute bacterial rhinosinusitis (ABRS)

Acute rhinosinusitis that is caused by, or is presumed to be caused by, bacterial infection. Diagnose ABRS when:

- Symptoms or signs of acute rhinosinusitis are present 10 days or more beyond the onset of upper respiratory tract symptoms.

Or

- Symptoms or signs of acute rhinosinusitis worsen within 10 days after an initial improvement (double infection).

Adapted from Rosenfeld RM, et al. *Otolaryngol Head Neck Surg.* 2007.[4]

Timing of symptoms is one factor that can help distinguish between viral and bacterial causes of sinusitis, since the symptom complex is similar (see **Table 1**). Most of these infections begin with an upper respiratory tract infection. Patients whose sinus symptoms persist longer than 10 days after the onset of symptoms are more likely to have bacterial rhinosinusitis. In addition, those whose symptoms initially improve then relapse into greater severity (double infection) are also more likely to have bacterial sinusitis.[5] On physical examination, only the finding of frank pus in the nose favors bacterial sinusitis. Transillumination of the sinuses and sinus tenderness to percussion are not useful in the diagnosis of acute rhinosinusitis.

Cultures of purulent drainage can be helpful in directing therapy. On the other hand, the 2007 clinical practice guidelines from the Rhinosinusitis Task Force of the American Academy of Otolaryngology–Head and Neck Surgery point out that cultures of nasal drainage are not helpful in distinguishing viral from acute bacterial rhinosinusitis and do not typically correlate with cultures obtained directly from the maxillary sinus. This means that cultures from blown-out secretions or anterior rhinoscopy are not useful. Maxillary sinus cultures correlate better with endoscopically directed intranasal cultures, but this equipment is usually unavailable in a primary care office setting. We often obtain such cultures with antibiotic sensitivities from patients refractory to medical management, permitting culture-driven antibiotic selection.

Role of imaging in the diagnosis of acute bacterial rhinosinusitis. Clinical practice guidelines from the 2007 Task Force state that radiographic imaging should not be obtained for patients who meet diagnostic criteria for acute rhinosinusitis, unless a complication or an alternative diagnosis is suspected. The imaging study of choice in evaluating complicated acute sinusitis is a sinus CT scan. Sinus x-ray films (plain films) no longer play a role in diagnosing rhinosinusitis.

For patients with recurrent acute sinusitis, we typically obtain a sinus CT scan to assess for anatomical abnormalities contributing to obstruction of sinus outflow. These anatomical abnormalities can include concha bullosa (**Figure 1**) or aerated middle turbinates, Haller cells, narrow osteomeatal complexes, or septal deviation (**Figure 2**). CT scans also identify any underlying dental disease, such as periapical abscesses (**Figure 3**), that can contribute to maxillary sinusitis in addition to sinonasal masses, such as polyps and cysts (**Figure 4**).[6]

Most sinus CT scans obtained for the evaluation of rhinosinusitis are ordered for patients suspected of having chronic rhinosinusitis. The Lund-Mackay scoring system is often used to grade the severity of chronic rhinosinusitis on a scale of 0 to 2 with a maximum score of 1.7 The higher the number, the more severe the sinus disease and the greater the likelihood that more extensive sinus surgery will be required.

Treatment of acute viral rhinosinusitis. The current recommendation for treatment of acute viral rhinosinusitis is simply symptomatic management. There is no role for antibiotics. The color of the nasal drainage is not an indicator of the presence of bacteria. Oral or topical decongestants, mucolytics, pain and fever control with NSAIDs or acetaminophen, and saline rinses may provide relief of symptoms. A recent Cochrane review, however, found no acceptable evidence of efficacy of decongestant or antihistamine therapy in acute sinusitis in children, primarily because none of the 526 articles reviewed met inclusion criteria for this review.[8] Oral corticosteroid therapy has not been shown to be effective,[9] and weak evidence supports topical corticosteroid therapy.[10] Nasal saline irrigations can provide symptomatic improvement and, in children at least, significantly improve symptom scores.[11]

Treatment of acute bacterial rhinosinusitis. Acute bacterial rhinosinusitis re-

Figure 1 – A sinus CT scan shows concha bullosa of the middle turbinates.

Figure 2 – Rightward septal deviation narrows the nasal cavity along with narrowing of the osteomeatal complexes.

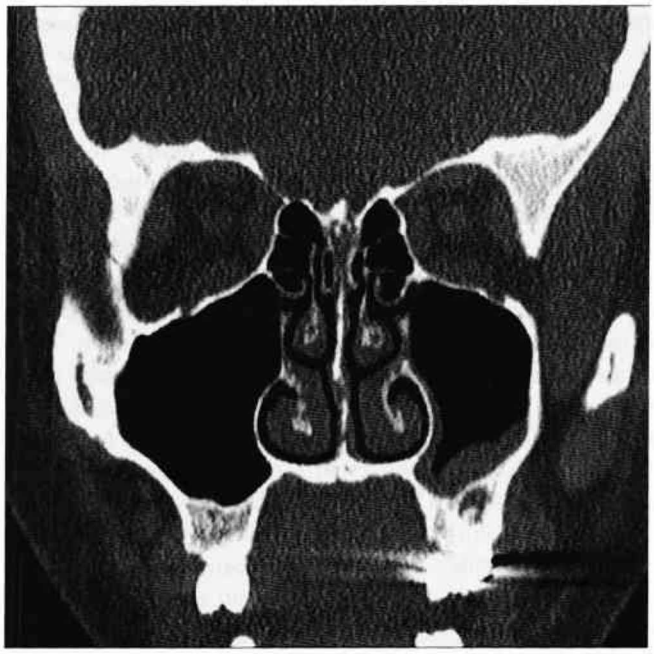

Figure 3 – A left molar periapical abscess has resulted in chronic inflammation of the left maxillary sinus.

Figure 4 – A large polyp in the left maxillary sinus extends into the nasal cavity.

solves best with antibiotic therapy. The most common organisms encountered in this setting are *Streptococcus pneumoniae, Haemophilus influenzae,* and *Moraxella catarrhalis.* Antibiotics are chosen based on their efficacy against these organisms. The first line of therapy is amoxicillin, which is typically given for a 10-day course. For patients with penicillin allergy, trimethoprim-sulfamethoxazole and macrolides are reasonable alternatives.

If a patient has taken antibiotics within the past 4 to 6 weeks, it is advisable to use a different antibiotic class, since either rapid recurrence or failure to completely resolve may indicate the presence of a resistant organism. We usually start a fluoroquinolone at this point, although amoxicillin-clavulanate is recommended as well. Adjunctive treatment with saline irrigation, mucolytics, topical and oral corticosteroids, and topical or oral decongestants and pain management are also recommended. If symptoms fail to improve after 7 days of therapy, then the patient should be reassessed.[12]

Complications of acute bacterial

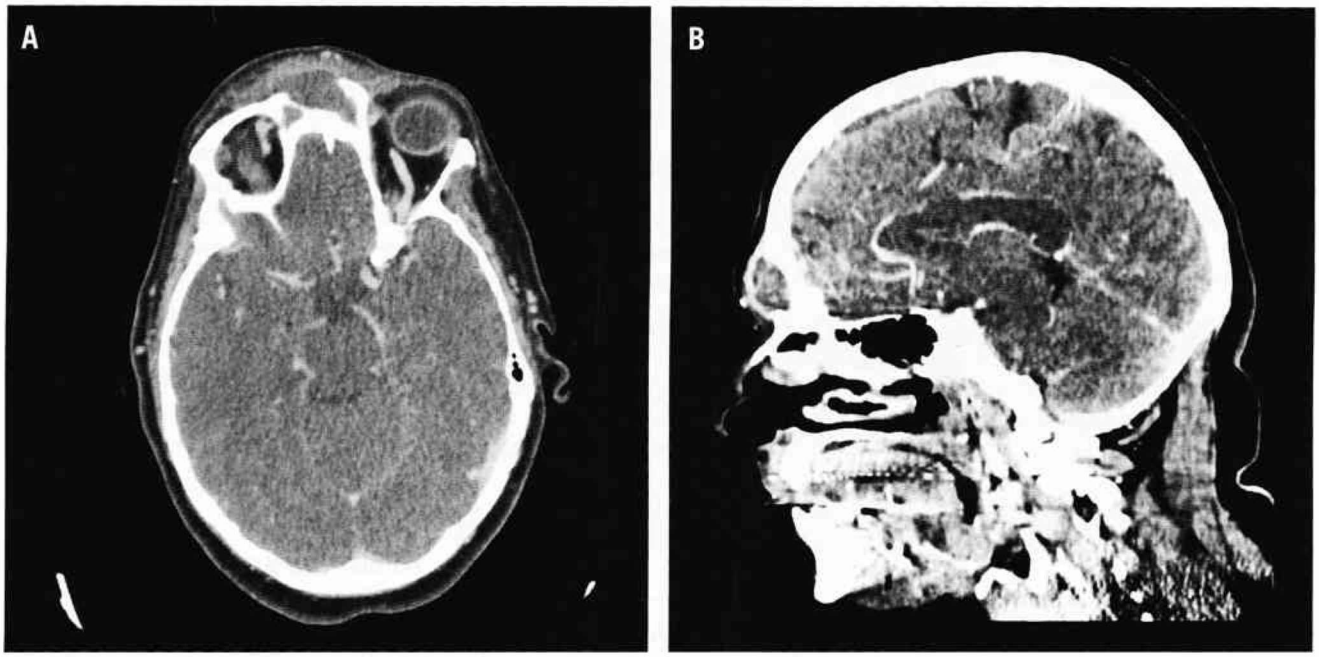

Figure 5 – An axial view of a Pott's puffy tumor shows a defect of the anterior table of the frontal sinus with a mucopyocele (A). A sagittal view is also shown (B).

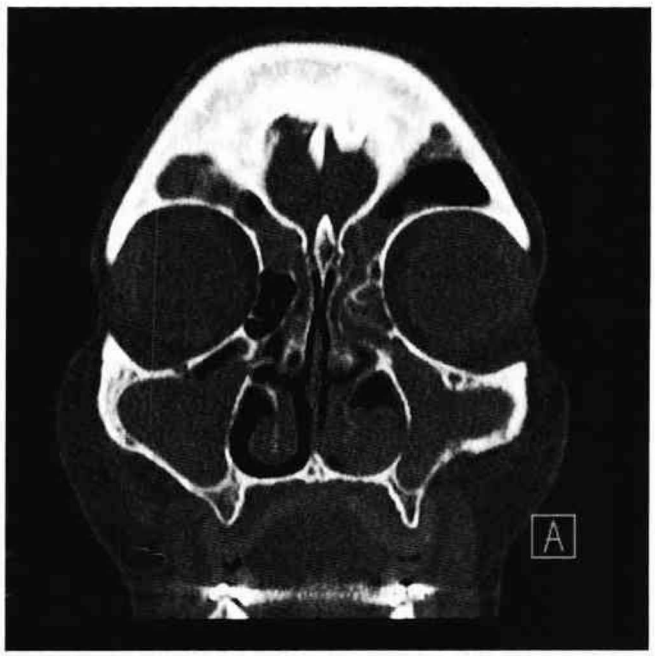

Figure 6 – A sinus CT scan of a patient with chronic sinusitis demonstrates obstruction of outflow tracts leading from the frontal sinus and the maxillary sinus in addition to opacification of the ethmoid sinuses within the concha bullosa. This patient also has a polypoid mass in the left nasal cavity underneath the inferior turbinate.

rhinosinusitis. Complications of acute bacterial rhinosinusitis are uncommon but can have catastrophic outcomes. As with all complications, awareness of possibilities and early recognition when they do occur facilitate satisfactory resolution. Complications are local, orbital, or intracranial. Local complications of acute bacterial rhinosinusitis include mucoceles, mucopyocele, and osteomyelitis of the bone. Pott's puffy tumor is a specific bone infection following complicated frontal sinusitis, resulting in a mucopyocele within the sinus and osteomyelitis of the anterior table of the frontal sinus, which can progress to involve the posterior table. Affected patients usually have a history of recurrent or chronic sinusitis with acute onset of tenderness and swelling of the forehead (**Figure 5**).

Orbital complications can be divided into categories based on Chandler classification grades (**Table 2**).[13] Although antibiotics can sometimes successfully resolve complications in groups 1 and 2, surgical intervention is required for the others.

Intracranial complications of rhinosinusitis include subdural and epidural abscesses and meningitis. Surgical drainage is usually required for resolution of abscesses.[14]

CHRONIC RHINOSINUSITIS

Diagnosis. Chronic rhinosinusitis can have a negative impact on a patient's quality of life similar to that of other chronic conditions, such as heart disease. It is typically diagnosed on the basis of clinical criteria and a CT scan. The diagnosis requires that at least two of the following symptomatic criteria be present for at least 3 months:

- Nasal obstruction.
- Purulent drainage.
- Facial pain/pressure.
- Decreased sense of smell.

In addition, there should be at least one finding that confirms inflammation.[15] In a primary care setting this typically requires a sinus CT scan, but nasal endoscopy can also be used to evaluate for polyps, purulence, or edema. The sinus CT scan is usually done when the

Table 2 – Chandler's classification of orbital infection deriving from sinusitis

Group 1	Preseptal cellulitis	Inflammatory edema primarily limited to eyelid due to restricted venous drainage
Group 2	Orbital/postseptal cellulitis	Progressive inflammatory edema involving globe marked by chemosis
Group 3	Subperiosteal abscess	Collection of purulence between bone and periosteum with development of proptosis
Group 4	Orbital abscess	Collection of pus in orbital contents with onset of ophthalmoplegia
Group 5	Cavernous sinus thrombosis	Progression of inflammation intracranially with onset of fever, headache, and cranial nerve palsy

From Chandler JR, et al. *Laryngoscope.* 1970.[13]

patient is least symptomatic, often at the end of a course of antibiotics. If, however, referral to a rhinologic surgeon is already planned, it may be better to wait for the consultant to order the scan. Many surgeons use an intraoperative CT-based image guidance system, which requires a special CT protocol, so the patient could end up getting two sinus CT scans within a short time span.

Medical management. Chronic rhinosinusitis represents not just an infectious disease but also an inflammatory process. *Staphylococcus aureus* is a common bacterial organism in chronic rhinosinusitis. Therapy often includes antibiotics similar to those used for acute bacterial rhinosinusitis administered for a longer period of time. We typically initiate antibiotic therapy for 3 weeks with or without an oral corticosteroid.

We usually try to manage any possible underlying inflammatory causes, including allergy, with topical nasal corticosteroid sprays and antihistamines. Adjunctive therapies with saline, decongestants, and mucolytics are also used. We prefer to administer saline via a sinus rinse bottle or machine (a variation on the Waterpik device), since high-pressure and high-volume irrigations have been shown to deliver better sinonasal outcomes than low-pressure, low-volume devices.[16]

Consider referral to an otolaryngologist for possible sinonasal surgery in patients with chronic rhinosinusitis refractory to medical management or in patients with recurrent acute bacterial rhinosinusitis who have anatomical abnormalities that contribute to sinusitis. Sinonasal surgery has been shown to significantly improve quality of life in these patients.[17]

Sinus surgery. The goal of sinus surgery is to improve sinonasal outflow or drainage by opening blocked sinus passages that result from prolonged infectious and inflammatory changes. Theoretically, the widened passages should prevent recurrent sinusitis and allow for better mucociliary clearance and aeration of the sinus cavities.

The maxillary, sphenoid, and frontal sinuses are, for the most part, single open chambers with at most one or two small bony divisions. Enlarging the opening from each of these sinuses into the nose is effective. The ethmoid sinuses, on the other hand, are like a honeycomb of small mucosa-lined bony cells. For ethmoid sinus disease, the small bony septations are removed, making a single larger chamber. For the most part, sinus surgery is performed through the nose endoscopically to avoid any external skin incisions.

The safety record of endoscopic sinus surgery is impressive—but it is true that the surgeon is working within millimeters of the eye, optic nerve, carotid and other vessels, and the brain. Detailed preoperative study of each patient's intranasal endoscopic examination and CT scan is imperative in planning such surgery. The intraoperative CT-guided imaging systems provide yet another level of surgical safety by allowing real-time navigation through the sinuses during the procedure.

Like all surgery, however, it is not to be undertaken lightly. A frank discussion between the patient and surgeon is necessary to determine the risk-benefit ratio for that patient and to discuss realistic expectations. Often nasal procedures such as septoplasty (the correction of a deviated septum) and turbinate reduction (decreasing the size of enlarged turbinates) are combined with sinus surgery to optimize sinonasal symptoms after surgery.

FACTORS THAT MAY PREDISPOSE TO OR EXACERBATE RHINOSINUSITIS

Allergy and immune dysfunction. Any patient with recurrent acute rhinosinusitis or chronic rhinosinusitis should be evaluated for underlying allergies and immunodeficiency or immune dysfunction. Allergy skin tests are preferred, but in vitro tests or radioallergosorbent tests may also be performed. We encourage environmental control measures and consistent medical management of allergies. For more severe allergic disease, immunotherapy can modify the immune response to environmental allergens, ultimately decreasing the sinonasal inflammatory response.

Humoral deficiencies are more commonly associated with chronic rhinosinusitis or recurrent acute bacterial rhinosinusitis: consider IgA deficiency, common variable deficiency, or hypogammaglobulinemia. Patients with HIV infection are also susceptible to recurrent or chronic sinus disease. Autoimmune disorders, such as Wegener's granulomatosis, may contribute to recurrent sinus disease and should be considered in patients with chronic rhinosinusitis and significant nasal crusting. Adjunctive medications such as methotrexate or cyclophosphamide may be beneficial in managing this disease process.

Acid reflux. Esophageal-nasal reflux has been demonstrated by the presence of pepsinogen in the nasopharynx and nasal cavity. The reflux of gastric contents into the nasal cavity has been

CLINICAL HIGHLIGHTS

- Acute rhinosinusitis is a clinical diagnosis, to be considered in the patient who presents with nasal congestion, purulent rhinorrhea or post-nasal drainage, and facial pain or pressure.
- Most cases of acute rhinosinusitis are viral and do not benefit from antibiotics.
- The use of sinus CT in acute rhinosinusitis is limited to those cases in which another diagnosis is also being considered or a complication is suspected.
- For acute bacterial rhinosinusitis, amoxicillin is a good first (empiric) antibiotic choice (trimethoprim-sulfamethoxazole and macrolides are alternatives for those with a penicillin allergy).
- Chronic rhinosinusitis is also primarily a clinical diagnosis, but confirmation by CT or nasal endoscopy is preferable before embarking on extended courses of antibiotic therapy.
- Underlying inhalant allergies, immune disorders, mucociliary clearance dysfunction, smoking, and possibly acid reflux may predispose to or exacerbate rhinosinusitis.
- For chronic rhinosinusitis, the CT scan is ideally performed when the patient is not acutely symptomatic to assess chronic changes in the sinuses that fail to respond to medical therapy.
- Since many surgeons use an intraoperative CT-based image guidance system, which requires a specific CT protocol, consider waiting to obtain a CT scan if a referral is planned.
- Sinus surgery provides effective symptom relief and infection resolution.

thought to be a causative factor in some patients with chronic sinusitis. A recent review article showed that the presence of pepsinogen seems to elicit a nasal reflex that results in increased mucus production, which has been demonstrated by the effect of proton-pump inhibitors on decreasing post-nasal drip.[18] There does not appear to be a direct correlation between acid reflux and the development of chronic sinusitis.

Disorders of mucociliary clearance. Abnormal mucociliary clearance can contribute to mucostasis and chronic rhinosinusitis. Primary ciliary dyskinesia is a rare autosomal recessive genetic disorder marked by structurally abnormal or absent cilia structure. Affected patients often present with recurrent bronchitis and other lower respiratory tract disease. Kartagener's syndrome represents a form of ciliary dyskinesia marked by situs inversus, bronchiectasis, and chronic sinusitis. Mucociliary clearance dysfunction also plays a role in recurrent lung and sinus infections in cystic fibrosis patients. Upper respiratory viral illnesses and smoking can also contribute to clearance dysfunction.

A rough gauge of mucociliary clearance time can be performed in the office by putting a small amount of saccharine onto the anterior-lateral nasal mucosa, just behind the dividing line between skin and respiratory mucosa. The amount of time that elapses before the patient detects a sweet taste is measured. In a study of healthy non-smokers, the central 50% of the sample tasted the sweetness between 12 and 20 minutes after saccharine placement.[19] Values over 30 minutes may indicate suboptimal mucociliary clearance. Smoking cessation, treatment of infection and allergies, and nasal saline irrigations may improve clearance.[20] ■

REFERENCES:

1. Ray NF, Baraniuk JN, Thamer M, et al. Healthcare expenditures for sinusitis in 1996: contributions of asthma, rhinitis, and other airway disorders. *J Allergy Clin Immunol.* 1999;103(3 pt 1):408-414.
2. Meltzer EO, Hamilos DL, Hadley JA, et al. Rhinosinusitis: establishing definitions for clinical research and patient care. *Otolaryngol Head Neck Surg.* 2004;131(6 suppl):S1-S62.
3. Lanza DC, Kennedy DW. Adult rhinosinusitis defined. *Otolaryngol Head Neck Surg.* 1997;117(3 pt 2):S1-S7.
4. Rosenfeld RM, Andes D, Bhattacharyya N. Clinical practice guideline: adult sinusitis. *Otolaryngol Head Neck Surg.* 2007;137:S1-S31.
5. Chow AW, Benninger MS, Brook I, et al. IDSA Clinical Practice Guideline for Acute Bacterial Rhinosinusitis in Children and Adults. *Clinical Infectious Diseases Advance Access.* Published March 20, 2012. http://www.idsociety.org/uploadedFiles/IDSA/Guidelines-Patient_Care/PDF_Library/IDSA%20Clinical%20Practice%20Guideline%20for%20Acute%20Bacterial%20Rhinosinusitis%20in%20Children%20and%20Adults.pdf.
6. Patel NA, Ferguson BJ. Odontogenic sinusitis: an ancient but under-appreciated cause of maxillary sinusitis. *Curr Opin Otolaryngol Head Neck Surg.* 2012;20:24-28.
7. Lund VJ, Kennedy DW. Staging for rhinosinusitis. *Otolaryngol Head Neck Surg.* 1997;117:S35-S40.
8. Shaikh N, Wald ER, Pi M. Decongestants, antihistamines and nasal irrigation for acute sinusitis in children (review). *Cochrane Database Syst Rev.* 2012 Sep 12;9:CD007909. doi: 10.1002/14651858.CD007909.pub3.
9. Venekamp PR, Thompson MF, Hayward G, et al. Systemic corticosteroids for acute sinusitis (review). *Cochrane Database Syst Rev.* 2011 Dec 7;(12):CD008115. doi: 10.1002/14651858.CD008115.pub2.
10. Hayward G, Heneghan C, Perera R, Thompson M. Intranasal corticosteroids in management of acute sinusitis: a systematic review and meta-analysis. *Ann Fam Med.* 2012;10:241-249.
11. Wang YH, Ku MS, Lun HL, Lue KH. Efficacy of nasal irrigation in the treatment of acute sinusitis in atopic children. *J Microbiol Immunol Infect.* 2012 30 Sept. Epub ahead of print.
12. Hickner JM, Bartlett JG, Besser RE, et al. Principles of appropriate antibiotic use for acute rhinosinusitis in adults: background. *Ann Intern Med.* 2001;134(6):498-505.
13. Chandler JR, Langenbrunner DJ, Stevens ER. The pathogenesis of orbital complications in acute sinusitis. *Laryngoscope.* 1970;80(9):1414-1428.
14. DelGaudio JM, Evans SH, Sobol SE, Parikh SL. Intracranial complications of sinusitis: what is the role of endoscopic sinus surgery in the acute setting. *Am J Otolaryngol.* 2010;31:25-28.
15. Wang X, Cutting GR. Chronic rhinosinusitis. *Adv Otorhinolaryngol.* 2011;70:114-121.
16. Rudmik L, Hoy M, Schlosser RJ, et al. Topical therapies in the management of chronic rhinosinusitis: an evidence-based review with recommendations. *Int Forum Allergy Rhinol.* 2013;3(4):281-298.
17. Soler ZM, Smith TL. Quality of life outcomes after functional endoscopic sinus surgery. *Otolaryngol Clin North Am.* 2010;43:605-612.
18. Hanna BC, Wormald PJ. Gastroesophageal reflux and chronic rhinosinusitis. *Curr Opin Otolaryngol Head Neck Surg.* 2012;20:15-18.
19. Valia PP, Valero FC, Pardo JM, Rentero DB, Monted CG. Saccharin test for the study of mucociliary clearance: reference values for a Spanish population. *Arch Bronconeumol.* 2008;44(10):540-545.
20. Talbot AR, Herr T, Parsons DS. Mucociliary clearance and buffered hypertonic saline solution. *Laryngoscope.* 1997;107:500-505.